

## Bioactive Collagen Dressing for the Treatment of Burns, Donor Sites and Ulcers

Subramanian Gunasekaran,<sup>1</sup> Prema Dhanraj,<sup>2</sup> Marilyn Kwolek<sup>3</sup>

<sup>1</sup>Encoll Corp., 4576 Enterprise St., Fremont, CA-94538, USA; <sup>2</sup> Professor and Head, Dept. Plastic Surgery, CMC, Vellore, TN, India; <sup>3</sup>Board Certified Dermatologist, Dublin, CA, USA

### Introduction:

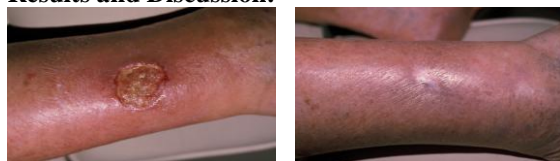
The chronic ulcers and the donor site wounds usually receive little medical attention and are often resulting in delayed healing with considerable pain and discomfort to the patients.<sup>1</sup> Accordingly the chronic ulcers and the donor site wounds have always been a topic of debate and various products have been used to find a solution. Acellular dermal replacement products mainly constituted of collagen are compared here and the findings are reported. For this report purposes, the commercially available "Helicoll collagen dressing" (claimed to be made of high purity native type-I collagen) was compared with other acellular dermal replacement dressings that are generally referred as "other collagen dressings".

### Materials and Methods:

Total of 124 patients constituting 64 ulcer cases and 60 donor-site cases were used for the study. Patients were selected at random at different centres and treated with varied acellular dermal replacement collagen dressings to compare the effectiveness of Helicoll collagen dressing with other collagen dressings.

An example case report as a general representation for the treatment of chronic ulcer of an 86 year old male patient with an ankle ulcer that remained indolent and expanded over a five month period has been provided here. He was first seen in the clinic on 06-08-2006 with the non-healing wound that measured 2.3 X 3.4 cm. He had been using different dressings for his ulcer treatment with unsuccessful results. The patient was seen again on 06-15-2006, by following standard oral medication. The size of the wound was not changed and site had some swelling. On 06-20-06 the wound size was found to be 2.3x3.3 cm and was continuing the same medication. The size of the wound when measured on 06-27-06 was found to be slightly enlarged and measured as 2.4 x 3.6 cm. Following periodic visits of the patient from 06-26-2006 to 09-07-2006, no significant improvement was noticed. On 09-18-2006, a collagen dressing namely HELICOLL was applied for the first time after soaking the dressing for 5 minutes in saline solution. The wound at that time was measured to have a size of 2.8 x 3.5 cm. During the successive visits, the rate of healing of the wound by Helicoll was monitored by the wound measurements.

### Results and Discussion:

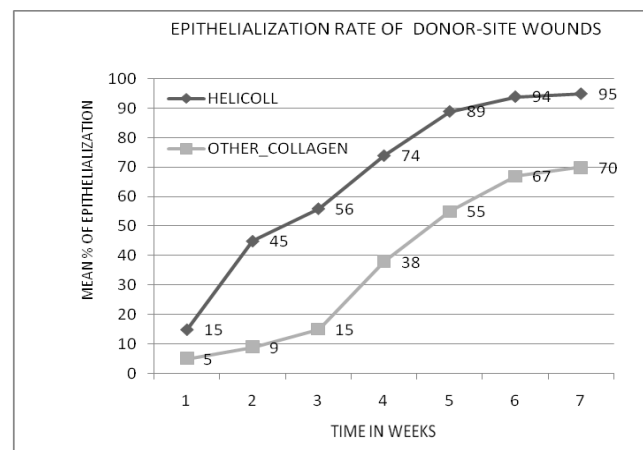
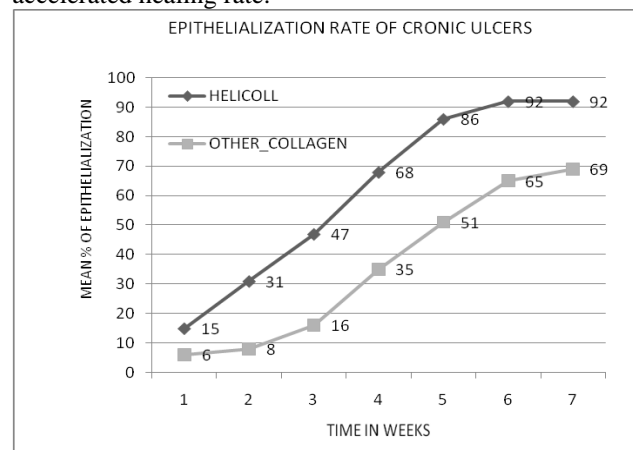


Before HELICOLL

After HELICOLL

The healing, either in the chronic ulcers or Donor site treatments, has been quite visible as early as 5th day of the HELICOLL treatment. There was no pain on opening the dressing and patients had no discomfort.

The other advantage of Helicoll is that the degradation product which forms is moist and non-adherent allowing the patient to move the donor site without any pain. It is evidenced that the Helicoll collagen dressing has achieved the maximum patient comfort level and accelerated healing rate.



### Conclusions / Summary:

How Helicoll Collagen may differ from other Collagen Dressings:

FEATURE	HELICOLL	Collagen plus Alginate	Cadaver Skin Prep.	Porcine Intestinal Mucosa	XL Collagen Dressings
Pure Type-I	Yes	No	No	No	No
Nativity of Collagen	Yes	No	No	No	No
Healing Rate	High	Low	Low	Low	Low
Native Attachment sites	High	Low or None	Low or None	Low or None	Low or None
Potential to Buffer excess glycosylation	High	Low or None	Low or None	Low or None	Low or None
Potential Cell Signaling	High	Low or None	Low or None	Low or None	Low or None

### References:

1. Gunasekaran, S. Collagen-Based Wound Dressings: How to Control Infection and Immune Response. In Donald Wise et al, ENCYCLOPEDIA HANDBOOK OF BIOMATERIALS AND BIOENGINEERING, Marcel Dekker Inc., NY, 1995, 2(A), 1267-1284.