

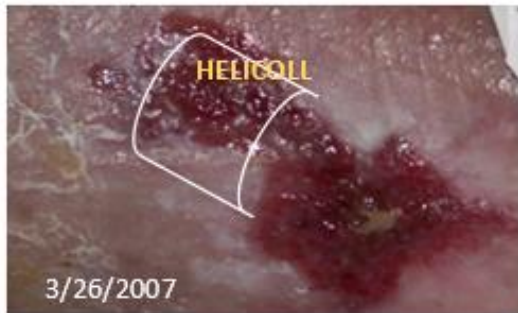A Case Report on Non-Healing Chronic Wound Treatment

Mathew Kelly, MD, Plastic Surgeon

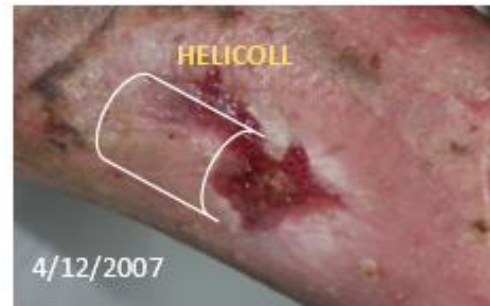Associate Professor & Co-Medical Director, Wound Care and Hyperbaric Medicine,
University of Alabama at Birmingham, AL

(Patient assisted by Jan Parks, RN, at St. Francis Memorial Hospital, San Francisco, CA)

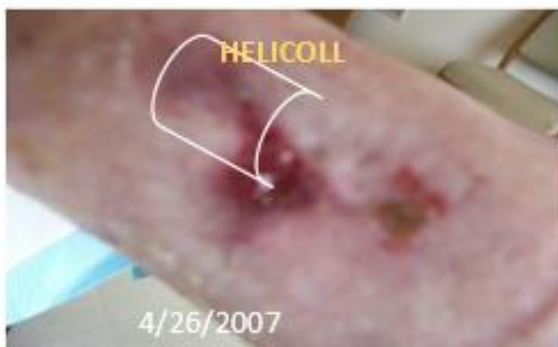Case: Non-Healing Leg Ulcer Wound - Male Patient, age 77



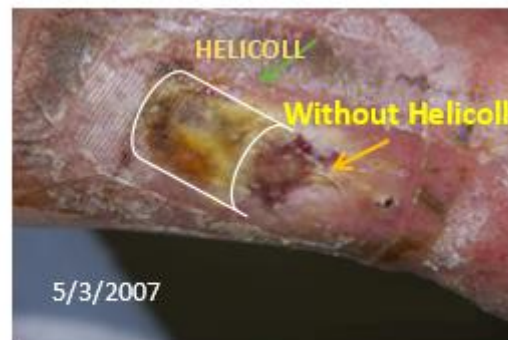
Helicoll dressing on half of the Wound to assess its efficacy



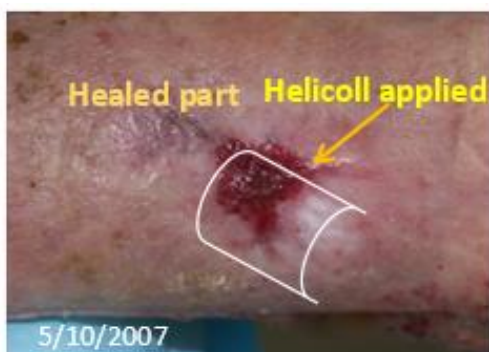Significant improvement seen on the Helicoll covered portion of the wound.



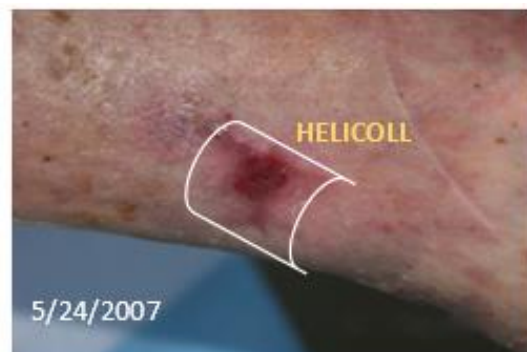Significant healing observed



Helicoll covered site was almost healed.

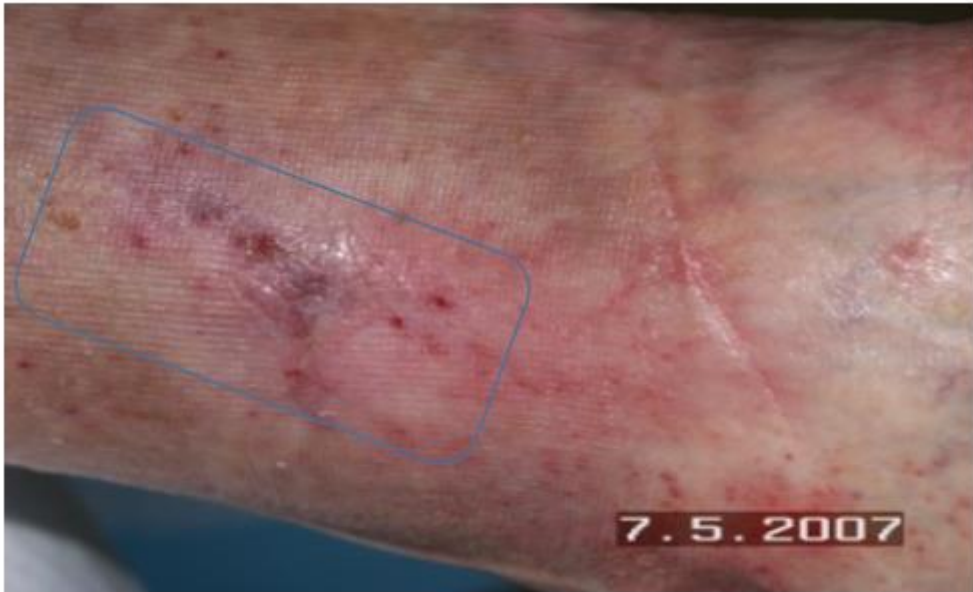

Helicoll covered site was totally healed.
Helicoll applied on the remaining Wound.



Complete healing of initially covered part.
Good Progress on later covered wound

Helicoll Prevented Recurrence of the Wound. Evidenced through several months of Follow up.



“This dressing can be recommended for the non-healing ulcer wound treatment”
- Mathew Kelly, MD